

# Arteriovenous Malformation of the Iris in 14 Cases

Jerry A. Shields, MD; Theodor F. E. Streicher, MD; Jane H. J. Spirkova, MD; Michal Stubna, MD; Carol L. Shields, MD

**Objective:** To report the clinical and fluorescein angiography features of arteriovenous (AV) malformation of the iris.

**Patients and Methods:** We reviewed the medical records and photographs of our patients with iris AV malformation. The iris lesion was classified as simple if the blood vessel made a loop only and complex if it made intertwining convolutions. We reviewed systemic and ocular findings in each case.

**Results:** Fourteen patients had an iris AV malformation. The mean age at diagnosis was 49 years (median age, 50 years; range, 16-79 years). All lesions were unilateral, without predilection for either eye or significant systemic associations. The lesion was classified as simple in 5 cases and complex in 9. The full extent of the lesion was not easily visualized with routine slitlamp examina-

tion. However, it was apparent with fluorescein angiography, which showed the vascular lesions to be uniformly hyperfluorescent in the early phases, with minimal or no late leakage of dye. There were typical areas of capillary nonperfusion in the iris stroma between the large abnormal vessels. A dilated episcleral blood vessel ("sentinel vessel") was noted in the quadrant of the iris lesion in 7 (50%) of the 14 cases. On follow-up ranging from 6 months to 14 years, none of the lesions changed or produced complications.

**Conclusions:** Iris AV malformation has characteristic clinical and fluorescein angiographic features. It appears to be a benign stationary condition that has no apparent systemic associations and no local complications.

*Arch Ophthalmol.* 2006;124:370-375

**A**RTERIOVENOUS (AV) MALFORMATION, variously called *racemose hemangioma*, *AV aneurysm*, and other terms, is a continuity between an artery and a vein, without an intervening capillary bed. It can occur in several areas of the body as a congenital or an acquired lesion. A well-known example in the ocular area is the retinal AV malformation that occurs as part of the Wyburn-Mason syndrome.<sup>1-4</sup> A true AV malformation of the iris is rare, and little has been published about this entity. We report the clinical manifestations of 14 patients with AV malformation in the iris who were examined and followed up by us.

## METHODS

We conducted a medical chart review of patients with iris AV malformation who underwent evaluation at Wills Eye Hospital, Bojnice Hospital, and Zilina Hospital. We defined iris AV malformation as 1 or more abnormally large iris blood vessels that passed from the anterior chamber angle for a variable distance toward the pupil, formed an abrupt loop, and returned to the angle. When there was direct continuation of the blood vessels with no complex arrangement of intertwining blood ves-

sels, we classified it as a simple iris AV malformation. If overlapping or intertwining of the vessels was present, we classified it as a complex AV malformation.

Inquiry was made regarding possible systemic and ocular associations. We tabulated the patient age at recognition of the lesion, sex, eye involved, referral diagnosis, iris color, type of AV malformation (simple or complex), location of AV malformation, fluorescein angiography findings, and follow-up.

## RESULTS

A summary of the features of the 14 patients with AV malformation is included in the **Table** and in **Figure 1**. The mean patient age at diagnosis was 49 years (median age, 50 years; range, 16-79 years). There were 9 male and 5 female patients. All lesions were unilateral, and there was no predilection for either eye. In 6 cases, the patient was referred specifically because findings were suggestive of iris or ciliary body melanoma. No patient had systemic cardiovascular disease, a history of extraocular vascular lesions, or findings of the Wyburn-Mason syndrome. No patient had iris atrophy or other iris abnormalities. The ocular fundus was normal bilaterally in all cases.

**Author Affiliations:** Oncology Service, Wills Eye Hospital, Thomas Jefferson University, Philadelphia, Pa (Drs J. A. and C. L. Shields); and Departments of Ophthalmology, Bojnice Hospital, Bojnice, Slovakia (Drs Streicher and Spirkova), and Zilina Hospital, Zilina, Slovakia (Dr Stubna).

**Table. Data on 14 Cases of Iris Racemose Hemangioma\***

Case No./ Age, y/Sex	Eye	Referral Diagnosis	Iris Color	Type of Lesion	Topographic Location	Meridian Location	No. of Clock Hours	Sclera	Follow-up, y
1/79/M	Right	Mm	Blue	Simple	Midzone	Temporal	3	Vessels	None
2/65/M	Right	Mm	Blue	Simple	Midzone	Temporal	3	Normal	14
3/40/M	Left	None	Blue	Complex	Pupil	Superonasal	2	Normal	14
4/50/F	Right	Mm	Brown	Complex	Midzone	Inferotemporal	1	Vessels	11
5/40/M	Left	None	Blue	Complex	Pupil	Temporal	1	Vessels	7
6/58/M	Left	Mm	Blue	Complex	Pupil	Temporal	1	Normal	None
7/41/M	Right	Mm	Blue	Complex	Pupil	Inferonasal	3	Vessels	4
8/30/F	Left	None	Blue	Simple	Pupil	Superotemporal	1	Normal	2
9/54/F	Left	None	Blue	Simple	Pupil	Inferior	2	Normal	10
10/50/F	Left	None	Blue	Simple	Pupil	Temporal	5	Normal	2
11/70/M	Right	None	Green	Complex	Pupil	Temporal	4	Normal	2
12/62/F	Right	Mm	Brown	Complex	Pupil	Nasal	3	Vessels	3
13/16/M	Right	None	Green	Complex	Pupil	Nasal	3	Vessels	5
14/32/M	Right	Cyst	Brown	Complex	Pupil	Superotemporal	2	Vessels	None

Abbreviation: Mm, melanoma.

\*The following systemic and ocular variables were reviewed but results were essentially negative in all cases: history of hypertension, diabetes mellitus, cardiovascular disease, carotid artery disease, ocular symptoms, chief complaint, visual acuity, intraocular pressures, cornea, anterior chamber, lens, vitreous, and fundus. Fluorescein angiography findings were consistent in all cases.

The iris AV malformation was classified as simple in 5 cases (cases 1, 2, 8, 9, and 10) and complex in the other 9 cases (Figure 1). All iris vessels appeared to originate in the anterior chamber angle, but it was not possible to determine whether they were continuous with the epibulbar vessels that were present in the quadrant of the iris lesion in 7 cases (cases 1, 4, 5, 7, 12, 13, and 14). In 11 cases, the AV malformation was near the pupillary margin, and in 3 cases, it was in the midzone of the iris (cases 1, 2, and 4). The iris was blue in 9 cases, brown in 3, and green in 2. Representative photographs and fluorescein angiograms of the iris lesions are shown in **Figures 2, 3, 4, 5, and 6**. Even in patients with blue irides, the vascular lesion was not fully visualized because it was partly obscured by the iris stroma. However, the lesions were clearly visualized with fluorescein angiography (Figures 2, 3, 4, 5, and 6).

Fluorescein angiographic findings were consistent in almost all patients. In 13 cases, there was rapid filling of the enlarged iris blood vessel (usually within 10 to 12 seconds after injection), rapid transit of dye through the vascular abnormality, and gradual resolution of the intravascular fluorescence with minimal or no leakage of dye or late staining of adjacent tissue. The only exception was case 13, a more complex AV malformation, in which there was more sluggish flow. All cases showed a relative absence of iris blood vessels in the early angiograms in the area of the AV malformation, especially in the area between the 2 major vessels of the lesion (Figures 2B, 3B, 5, and 6).

A dilated episcleral blood vessel ("sentinel vessel") was noted in the quadrant of the iris lesion in 7 (50%) of our 14 cases (**Figure 7**). It was this evident blood vessel that often prompted referral to rule out a ciliary body melanoma. However, ophthalmoscopy, ultrasonography, and transillumination were performed in all cases, and no melanoma was present in any of these 14 patients.

On follow-up (mean, 8 years; median, 7 years; range, 1-14 years), none of the lesions showed change. There

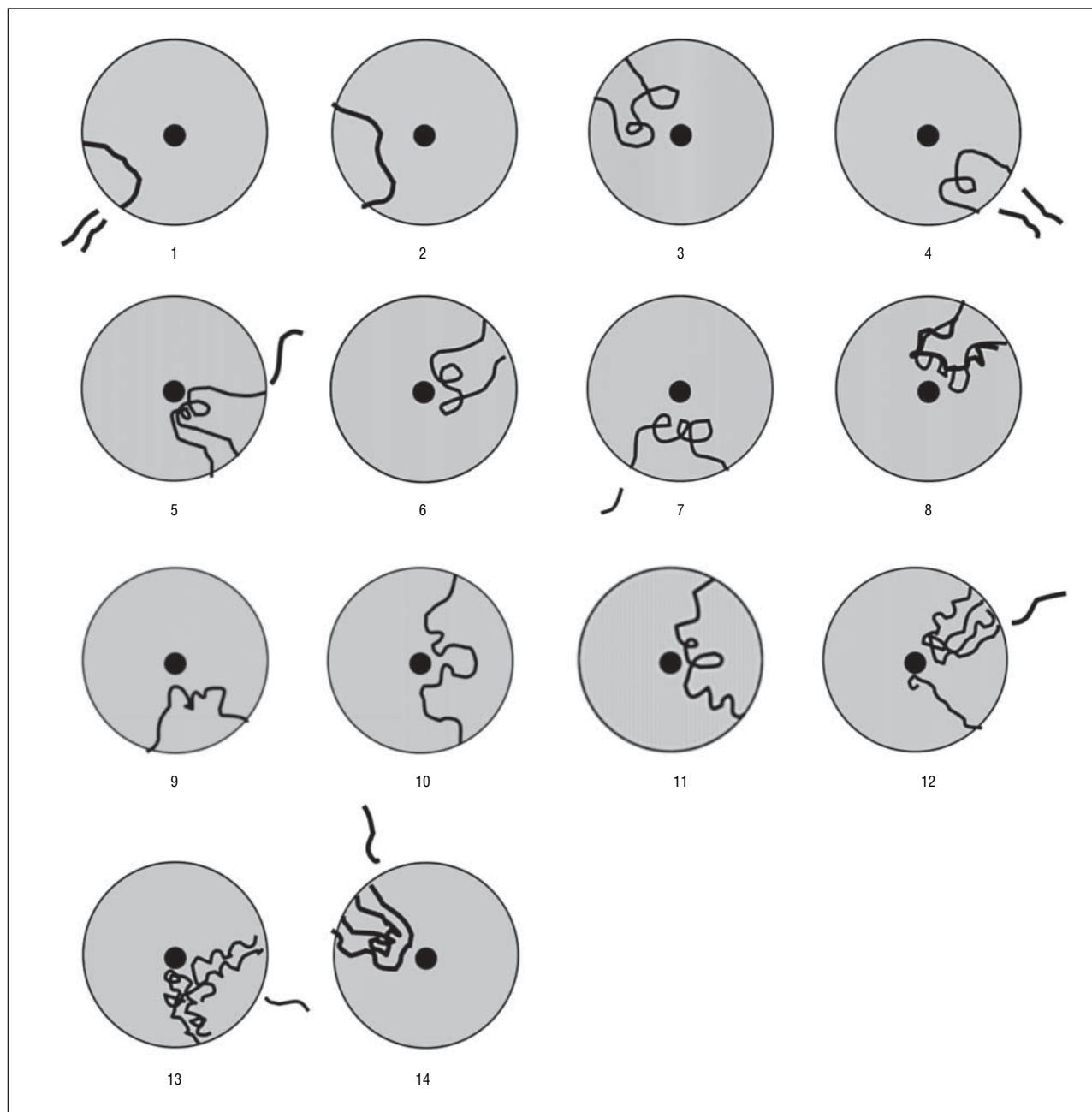
was no hyphema, inflammation, posterior synechia, angle closure, or other iris abnormality.

## COMMENT

The lesions described herein appear to be unusual AV malformations in the iris stroma. Some authors<sup>1-4</sup> have used terms such as *racemose hemangioma*, *cirroid hemangioma*, and *AV aneurysm* to describe similar lesions in the retina. Archer and associates<sup>4</sup> divided retinal AV communications into 3 groups. Group 1 was characterized by the interposition of an arteriolar or abnormal capillary plexus between the major communicating vessels. Group 2 was typified by direct AV communication without the interposition of capillary or arteriolar elements. Group 3 included more complex AV communications associated with severe visual loss. By strict definition, the lesions in this series are not true neoplasms and they are not localized balloonlike dilatations as seen with aneurysms. Therefore, we elected to use the term *AV malformation*.

The most common tumors and pseudotumors of the iris are melanocytic nevus, melanoma, and iris pigment epithelial cysts; other benign and malignant neoplasms of the iris are considerably less common. Iris vascular tumors are exceptionally uncommon, and their actual existence has been questioned. In 1972, Ferry<sup>5</sup> reviewed 10 cases of iris "hemangiomas" that were published at that time. He was able to retrieve tissue for further review in most cases and found that the lesions actually were examples of hemorrhagic melanoma, juvenile xanthogranuloma, or reactive vascular proliferation. He concluded that no reported case of iris hemangioma appeared to be acceptable as a case of true iris hemangioma, except for 1 iris cavernous hemangioma in a Doberman pinscher.

Since the report by Ferry<sup>5</sup> was published, we have looked for cases of iris vascular tumors and pseudotumors in our clinical practice of ocular oncology and have identified examples of virtually all types of heman-



**Figure 1.** Location and distribution of the 14 cases of iris arteriovenous communication. The lines outside the circles in 7 cases represent episcleral blood vessels ("sentinel vessels").

gioma that are known to involve the retina.<sup>6</sup> There have been other reports of iris capillary hemangioma,<sup>7</sup> cavernous hemangioma,<sup>8-15</sup> varix,<sup>16,17</sup> and racemose hemangioma (AV malformation).<sup>18-23</sup>

The iris AV malformations reported herein have clinical features that seem identical to the AV malformation of the retina.<sup>1-4</sup> Like those in the retina, the iris AV malformation can be a simple AV communication or a more complex arrangement of anastomosing vessels.

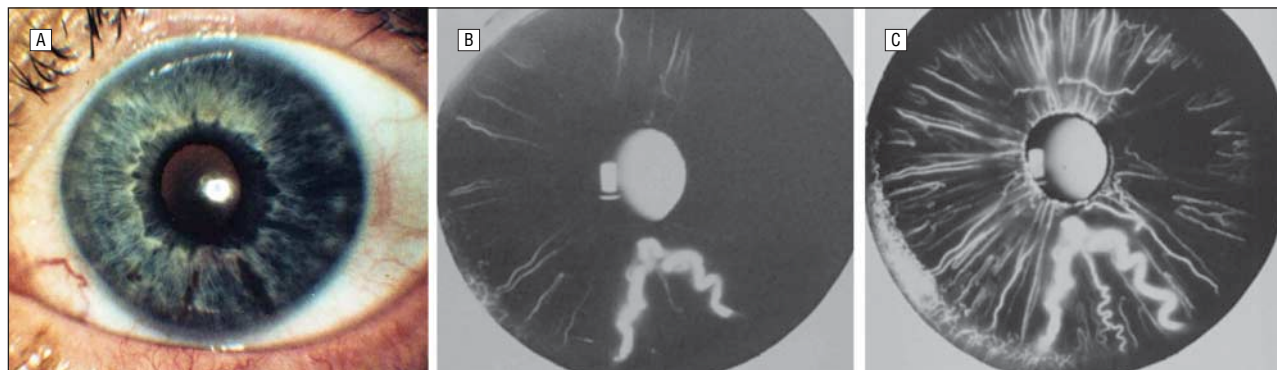
Hence, we chose to classify them as simple or complex. The complex type appears to be more common, accounting for 9 of our 14 cases (Table). Our cases of iris AV malformation correspond to the group 2 classification of Archer and associates<sup>4</sup> for retinal AV malforma-

tion. Prost,<sup>19</sup> in his well-documented case report, came to the same conclusion.

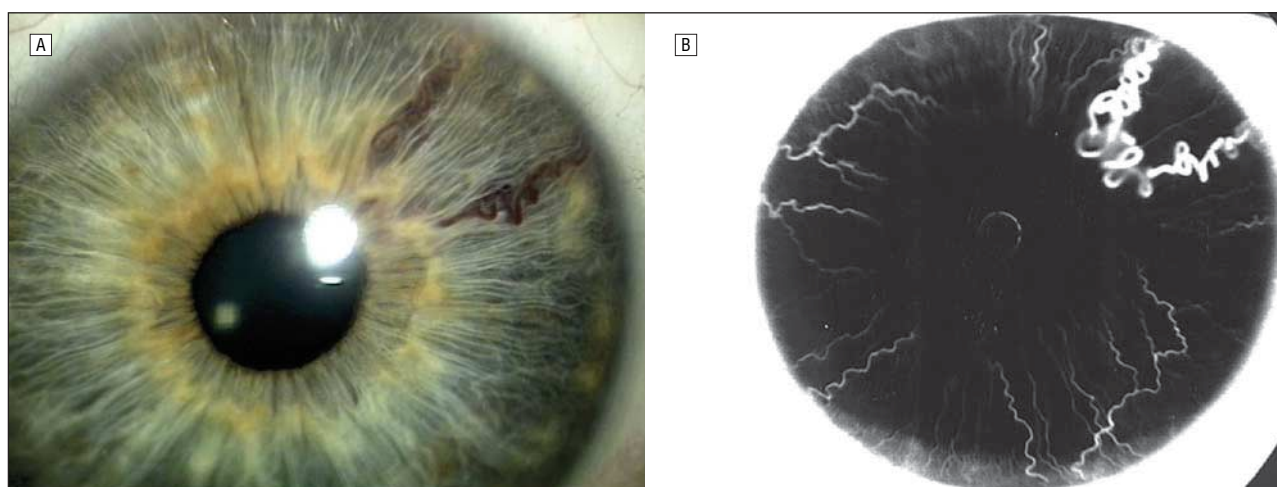
Our patients had no systemic associations that appeared to be related to the iris lesions. One patient had borderline systemic hypertension that required no treatment, 1 had colon cancer, and 1 had Addison disease. None of our patients, and none of the other reported cases of iris AV malformations,<sup>18-23</sup> had evidence of intracranial AV malformations or other signs suggestive of Wyburn-Mason syndrome.

The majority of iris AV malformations extended from the anterior chamber angle to the pupillary region. There was a predilection for the lesion to be located in the temporal half of the iris, and most occupied less than one fourth

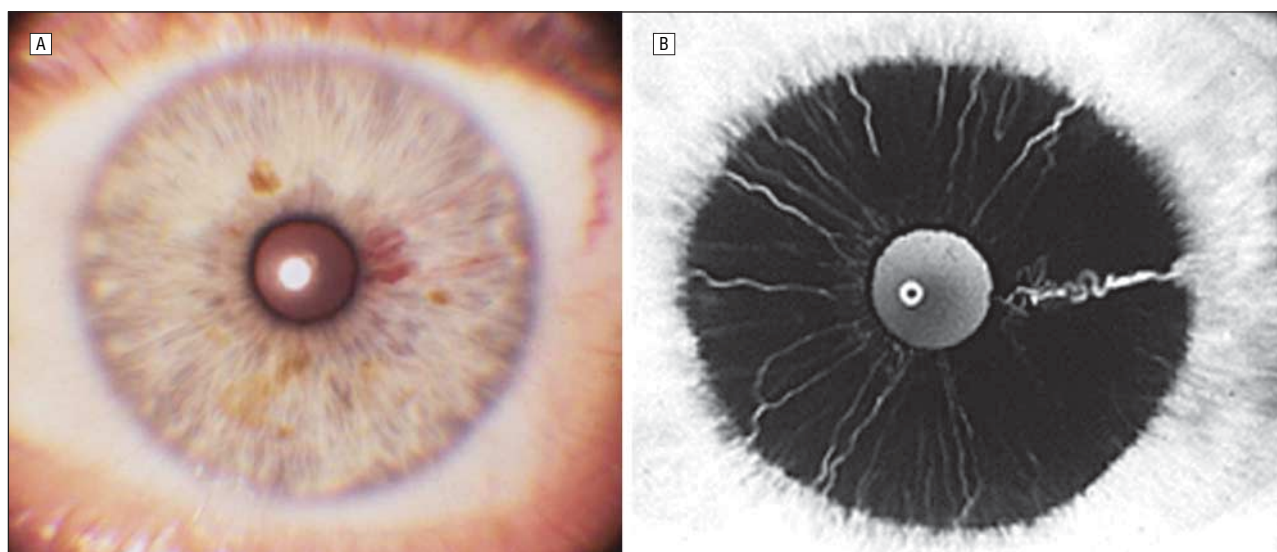




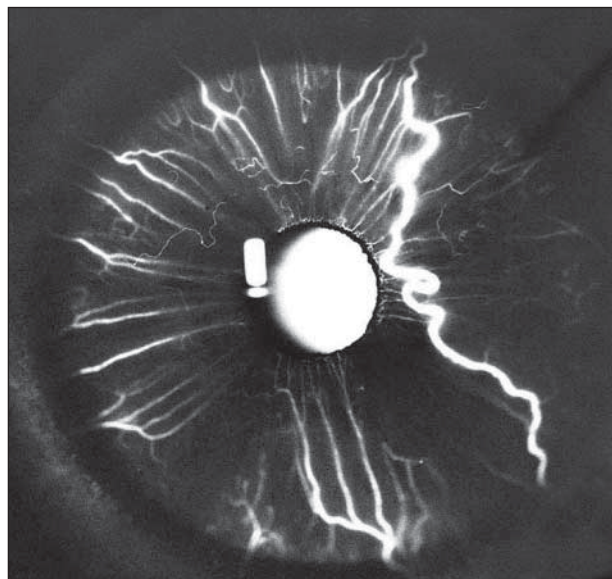
**Figure 2.** Simple iris arteriovenous (AV) communication (case 9). A, Clinical appearance of large iris blood vessels inferiorly. The entire lesion is difficult to visualize. B, Early fluorescein angiogram showing fluorescence of vascular channel. The normal radial blood vessels of the iris are just beginning to fill with dye. C, Later fluorescein angiogram showing only minimal leakage from the AV communication. The normal radial iris vessels are filled with fluorescein and are not leaking dye.



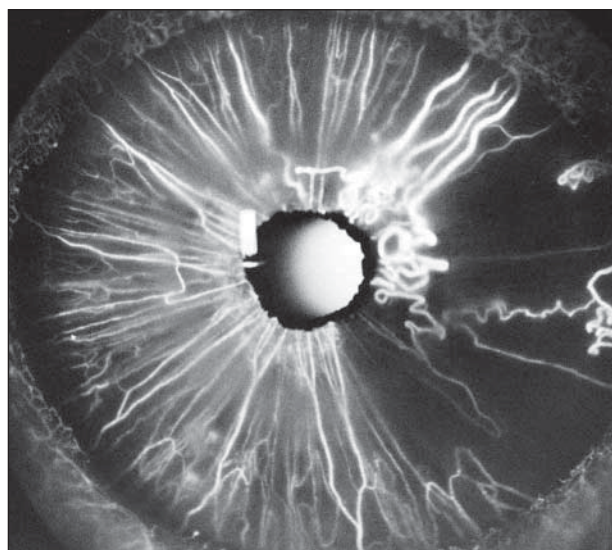
**Figure 3.** Complex arteriovenous (AV) communication (case 8). A, Clinical appearance of large superotemporal complex iris AV communication. It is not possible to visualize any communicating vessels near the pupil. B, Fluorescein angiogram more clearly depicting the complex arrangement of blood vessels near the pupil.



**Figure 4.** Superotemporal complex iris arteriovenous (AV) communication (case 5). A, Clinical appearance. In contrast to case 8 (shown in Figure 3), the vascular component near the pupil is visualized, but the feeder vessels coming from the angle are not. B, Fluorescein angiogram showing distinct vessels emanating from the angle that were not evident clinically.



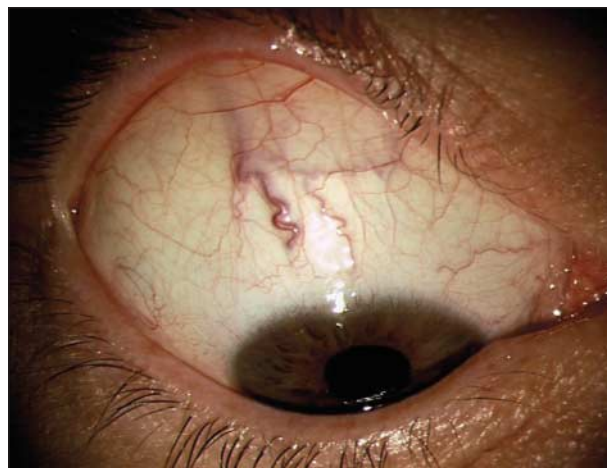**Figure 5.** Fluorescein angiogram of case 10.



**Figure 6.** Fluorescein angiogram of case 13.

of the iris (Table and Figure 1). We have no explanation for this distribution. There were prominent episcleral blood vessels located in the quadrant of the iris abnormality in at least 7 of our 14 cases. It is well known that such sentinel vessels can be an underlying sign of a ciliary body melanoma. However, there was no intraocular tumor present in our cases, as determined by indirect ophthalmoscopy, gonioscopy, transillumination, and ultrasonography. Although it would be difficult to prove, we suspect that the episcleral blood vessels were continuous with the iris blood vessel in our cases. In support of that speculation, other authors were able to demonstrate gonioscopically a communication between an iris AV malformation and a prominent episcleral vessel.<sup>18,19</sup>

Most of the patients in our series had blue irides (Table). The lesions were more easily visualized clinically in blue irides compared with darker irides. Even in a blue iris, however, the lesion was often not seen in its



**Figure 7.** Episcleral ("sentinel") blood vessel in case 14.

entirety, and fluorescein angiography was instrumental in revealing the full extent of the lesion. We suspect that these lesions are more easily detected on slitlamp biomicroscopy in a blue iris, but are not necessarily more common in a blue iris than in a brown iris.

Fluorescein angiography of iris AV malformations revealed that the affected vessels were generally competent, showing minimal or no leakage of dye. There was rapid flow of fluorescein through the feeding artery and the draining vein. In case 13, however, there was more sluggish flow. We are uncertain as to why the flow was more sluggish in that case, but it was one of the more complex vascular patterns in our series and may have been predisposed to more stagnant blood flow or thrombosis. That case appears to be unique, in that the anatomic distribution and angiographic findings differ from those of the other cases mentioned in the literature. A consistent finding on fluorescein angiography was a broad area of absence or atypical distribution of iris blood vessels in the area between the 2 main components of the vascular lesion. We speculate that these large vessels shunted blood from small capillaries, leading to capillary non-perfusion in the affected area. We have observed a similar absence of small blood vessels in retinal AV malformation. As implied earlier, no patient had iris atrophy, iris neovascularization, or other changes to suggest severe vascular occlusion.

It is unclear whether iris AV malformation is acquired or congenital. There are relative arguments in favor of an acquired origin. First, several of our patients had a history of examinations by eye specialists in which the lesion was not detected. Second, our patients were middle-aged or elderly. Eight of the 14 patients were 50 years or older when the lesion was first detected.

There may be more convincing factors in favor of a congenital origin. First, the iris AV malformation is remarkably similar, clinically and angiographically, to the retinal racemose hemangioma, which is believed to be a congenital malformation that is present at birth or develops in very early childhood. Acquired vascular changes, such as iris neovascularization, have a different vascular pattern, and they tend to show florid leakage of fluores-



cein. Second, no patient had systemic or ocular vascular disease that could have predisposed to an iris vascular alteration. Third, the lesion is often quite subtle and largely hidden in the iris stroma. Hence, it could be overlooked until adulthood, when a person is more likely to undergo a detailed slitlamp examination. It is possible that iris AV malformation develops during embryogenesis as a response to a localized failure of iris vascularization, with secondary dilation of adjacent blood vessels to circumvent the defective capillary zone.<sup>19</sup>

The clinical features of iris AV malformation are characteristic. However, the differential diagnosis should include the other iris vascular tumors and pseudotumors. Iris capillary hemangioma is a redder, more diffuse or circumscribed mass that can occur in the irides of infants who have periocular cutaneous capillary hemangioma. Like the cutaneous counterpart, it tends to regress in early childhood.<sup>7</sup> Iris cavernous hemangioma occurs as a small grapelike vascular tuft, usually at the pupillary border.<sup>8-15</sup> About 10% of patients have myotonic dystrophy,<sup>14</sup> and 20% have diabetes mellitus.<sup>15</sup> Iris varix is a solitary, more rounded lesion that involves a vein and does not show a dilating feeding artery. It generally becomes clinically apparent after bleeding or thrombosis, producing a hematoma-like lesion.<sup>16,17</sup>

Iris melanoma is typically a solid mass that may have prominent vascularity, but the classic AV malformation is not seen. The prominent epibulbar blood vessels, seen in some patients with iris AV malformation, can also raise suspicion of an underlying ciliary body melanoma. However, the sentinel vessels seen with melanoma are generally larger and more prominent. All patients with prominent epibulbar vessels in the ciliary body area should undergo a detailed peripheral fundus examination and transillumination to exclude a ciliary body melanoma. In our series, 6 of the 14 patients were referred specifically because of the possibility of iris or ciliary body melanoma. We believe that some of the other cases were referred because of findings suggestive of melanoma, but the referral diagnosis was not specified.

We observed no local complications of iris AV malformation. None showed progression, hyphema, increased intraocular pressure, iris atrophy, iris neovascularization, or other complications. The retinal AV malformation also has a similar benign course in most cases.<sup>23</sup> However, in rare cases it can cause complications such as vitreous hemorrhage and retinal vein obstruction.<sup>24,25</sup>

Our observations suggest that iris AV malformation may be more common than previously believed. In all of our patients, the lesion was detected as a coincidental finding on routine slitlamp biomicroscopy. It appeared relatively subtle, being partially obscured by the adjacent iris stroma. Fluorescein angiography, however, clearly depicted the full extent of the lesion. With increased awareness of iris AV malformation, we believe that it will be recognized more often in the future.

Since this manuscript was accepted for publication, the authors have evaluated 4 additional cases of iris AV malformation. Our findings in these additional cases were similar to those of the 14 patients described herein.

**Submitted for Publication:** February 12, 2004; final revision received March 9, 2005; accepted March 17, 2005.

**Correspondence:** Jerry A. Shields, MD, Ocular Oncology Service, Wills Eye Hospital, 840 Walnut Street, Philadelphia, PA 19107 (jas.cls@comcast.net; jerryshields@comcast.net).

**Financial Disclosure:** None.

**Funding/Support:** This study was supported by the Eye Tumor Research Foundation, Philadelphia, Pa (Drs J. A. Shields and C. L. Shields), the Award of Merit in Retina Research, Houston, Tex (Dr J. A. Shields), and the Macula Foundation, New York, NY (Dr C. L. Shields).

**Previous Presentation:** This study was presented as part of the 2004 Alvaro Rodriguez, MD, Gold Medal Award Lecture; February 12, 2004; Bogotá, Colombia.

## REFERENCES

- Gass JDM. Retinal arteriovenous aneurysm. In: Gass JDM, ed. *Stereoscopic Atlas of Macular Diseases*. 2nd ed. St Louis, Mo: Mosby-Year Book Inc; 1997:440-441.
- Shields JA, Shields CL. Vascular tumors of the retina and optic disc. In: Shields JA, Shields CL, eds. *Intraocular Tumors: A Text and Atlas*. Philadelphia, Pa: WB Saunders Co; 1992:393-419.
- Shields JA, Shields CL. Systemic hamartomatosis ("phakomatosis"). In: Shields JA, Shields CL, eds. *Intraocular Tumors: A Text and Atlas*. Philadelphia, Pa: WB Saunders Co; 1992:513-539.
- Archer DB, Deutman A, Ernest JT, Krill AE. Arteriovenous communications of the retina. *Am J Ophthalmol*. 1973;75:224-241.
- Ferry AP. Hemangiomas of the iris and ciliary body: do they exist? a search for a histologically proved case. *Int Ophthalmol Clin*. 1972;12:177-194.
- Shields JA, Shields CL. Iris hemangioma. In: Shields JA, Shields CL, eds. *Atlas of Intraocular Tumors*. Philadelphia, Pa: WB Saunders Co; 1999:260-263.
- Ruttum MS, Mittelman D, Singh P. Iris hemangiomas in infants with periorbital capillary hemangiomas. *J Pediatr Ophthalmol Strabismus*. 1993;30:331-333.
- Rosen E, Lyons D. Microhaemangiomas at the pupillary border. *Am J Ophthalmol*. 1969;67:846-853.
- Prost M. Cavernous hemangioma of the iris. *Ophthalmologica*. 1987;195:183-187.
- Lam S. Iris cavernous hemangioma in a patient with recurrent hyphema. *Can J Ophthalmol*. 1993;28:36-39.
- Bandello F, Brancato R, Lattanzio R, Maestranzi G. Laser treatment of iris vascular tufts. *Ophthalmologica*. 1993;206:187-191.
- Ah-Fat FG, Canning CR. Recurrent visual loss secondary to an iris microhaemangioma. *Eye*. 1994;8:357.
- Larson SA, Oetting TA. Presumed iris hemangioma associated with multiple central nervous system cavernous hemangiomas. *Arch Ophthalmol*. 2002;120:984-985.
- Cobb B, Shilling JS, Chisholm IH. Vascular tufts at the pupillary margin in moronic dystrophy. *Am J Ophthalmol*. 1970;69:573-582.
- Coleman SL, Green WR, Patz A. Vascular tufts of pupillary margin of iris. *Am J Ophthalmol*. 1977;83:881-883.
- Andersen SR, Other A. Varix of the iris. *Arch Ophthalmol*. 1975;93:32-33.
- Shields JA, Shields CL, Pulido J, Eagle RC Jr, Nothnagel AF. Iris varix simulating an iris melanoma. *Arch Ophthalmol*. 2000;118:707-710.
- Stur M, Strasser G. Sectorial racemose vascular malformation of the iris. *Klin Mbl Augenheilk*. 1983;183:50-52.
- Prost M. Arteriovenous communication of the iris. *Br J Ophthalmol*. 1986;70:856-859.
- Streicher T, Spirkova J, Markechova G. Abnormal vessels in the iris in angiographic imaging. *Cesk Oftalmol*. 1993;49:8-12.
- Shields JA, Shields CL, O'Rourke T. Racemose hemangioma of the iris. *Br J Ophthalmol*. 1996;80:770-771.
- Brancato R, Bandello F, Lattanzio R. Abnormal vessel patterns. In: Brancato R, Bandello F, Lattanzio R, eds. *Atlas of Iris Fluorescein Angiography*. Amsterdam, the Netherlands: Kugler & Ghedini Publications; 1995:123-145.
- Shields JA, Shields CL. Retinal racemose hemangioma. In: Shields JA, Shields CL, eds. *Atlas of Intraocular Tumors*. Philadelphia, Pa: WB Saunders Co; 1999:186-187.
- Mansour AM, Wells CG, Jampol LM, Kalina RE. Ocular complications of arteriovenous communications of the retina. *Arch Ophthalmol*. 1989;107:232-236.
- Shah GK, Shields JA, Lanning R. Branch retinal vein obstruction secondary to retinal arteriovenous communication. *Am J Ophthalmol*. 1998;126:446-448.